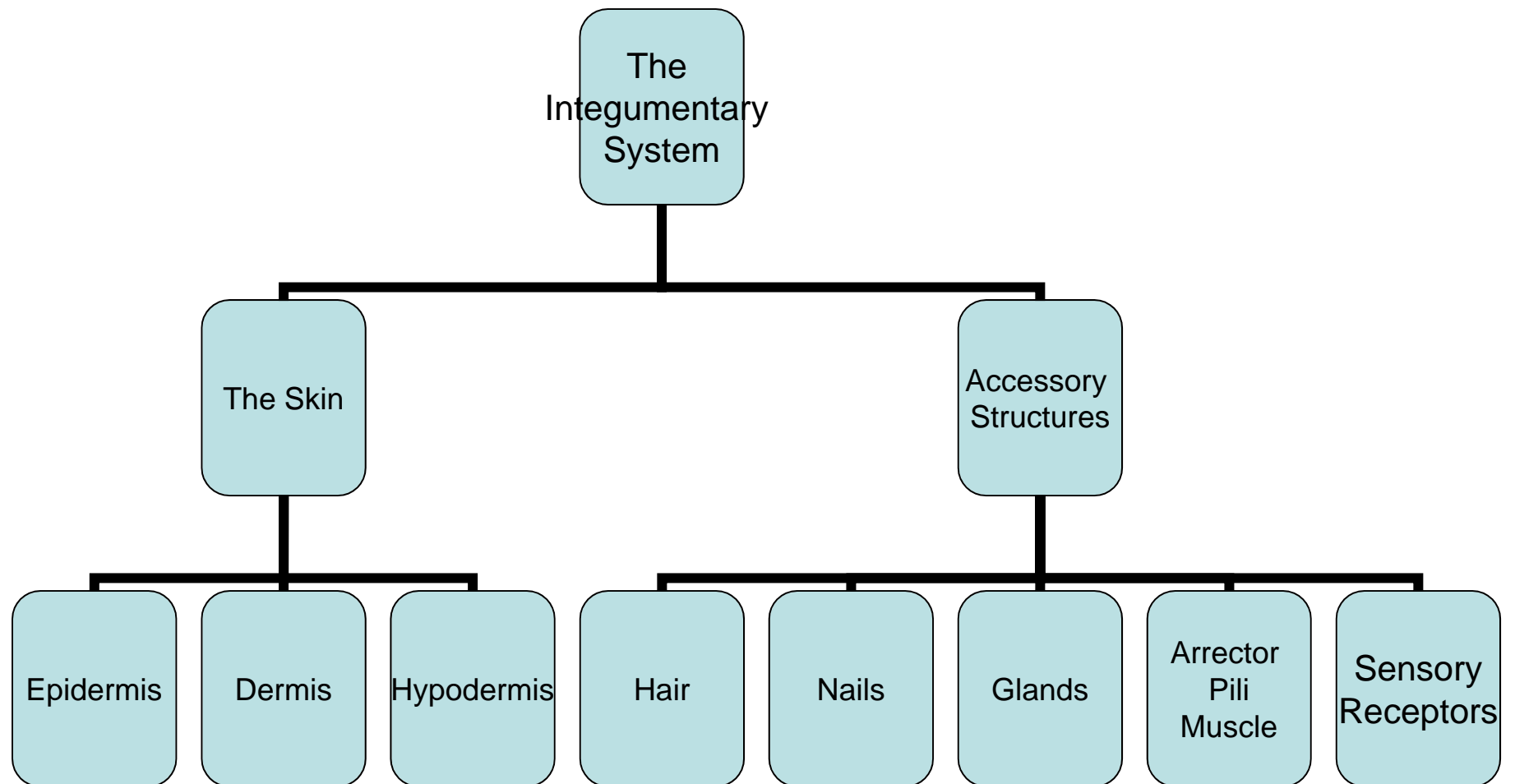


Chapter 5

The Integumentary System



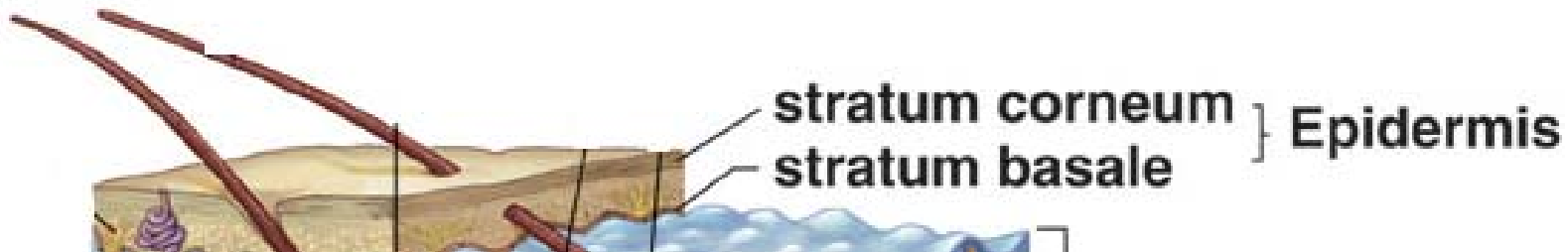
Section 5.1- Structure of the Skin

Skin

- Cutaneous membrane or integument
- Largest organ of the body
- 2 layers- **Epidermis** and **Dermis**
- **Hypodermis**- layer below the epidermis and dermis (not considered part of the skin)

Epidermis

- Uppermost layer
- **Stratified squamous keratinized ET**
- Composed of several layers
 - **Stratum Basale**- deepest layer
 - **Stratum Corneum**- outermost layer

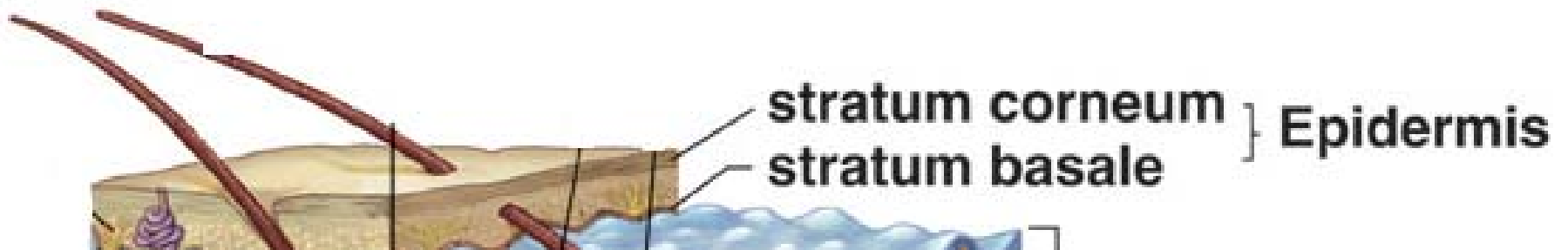


Epidermis- Stratum Basale

- Deepest layer
- **Cuboidal cells**
- Cells have good blood supply (**vascular**)
- Constant **mitosis**
 - What would happen as cells are dividing and pushed towards the surface away from their blood supply?
- Other Cells found in SB
 - **Langerhans cells**- macrophages
 - **Melanocytes**- produce melanin
 - **Keratinocytes**- produce keratin

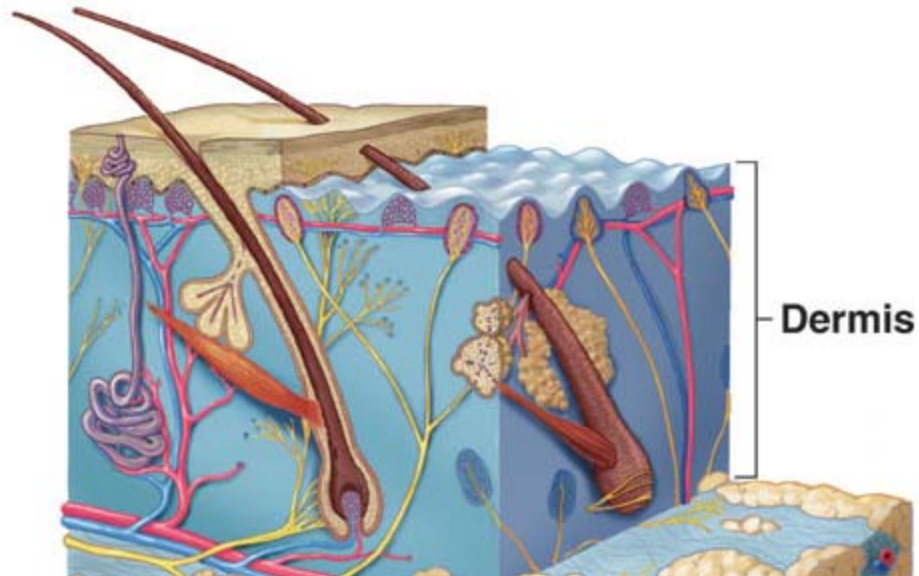
Epidermis- Stratum Corneum

- Hardening of squamous cells due to **keratinization**
 - **Keratin**
 - Waterproofs skin
 - Prevents water loss and water gain
 - Mechanical barrier against microbe invasion



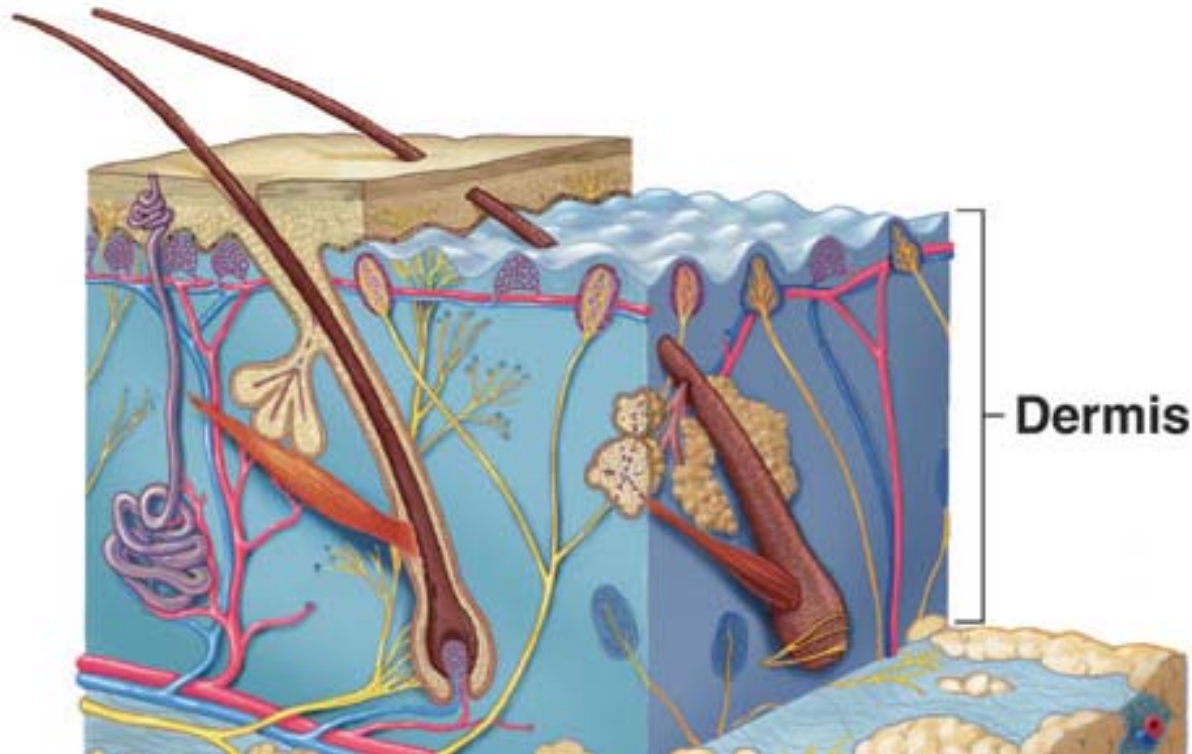
Dermis

- Deep to the epidermis
- Thicker layer consisting of dense irregular CT
- Upper layer of dermis- Dermal papillae- anchors dermis to epidermis
 - DP projects into fingerprints



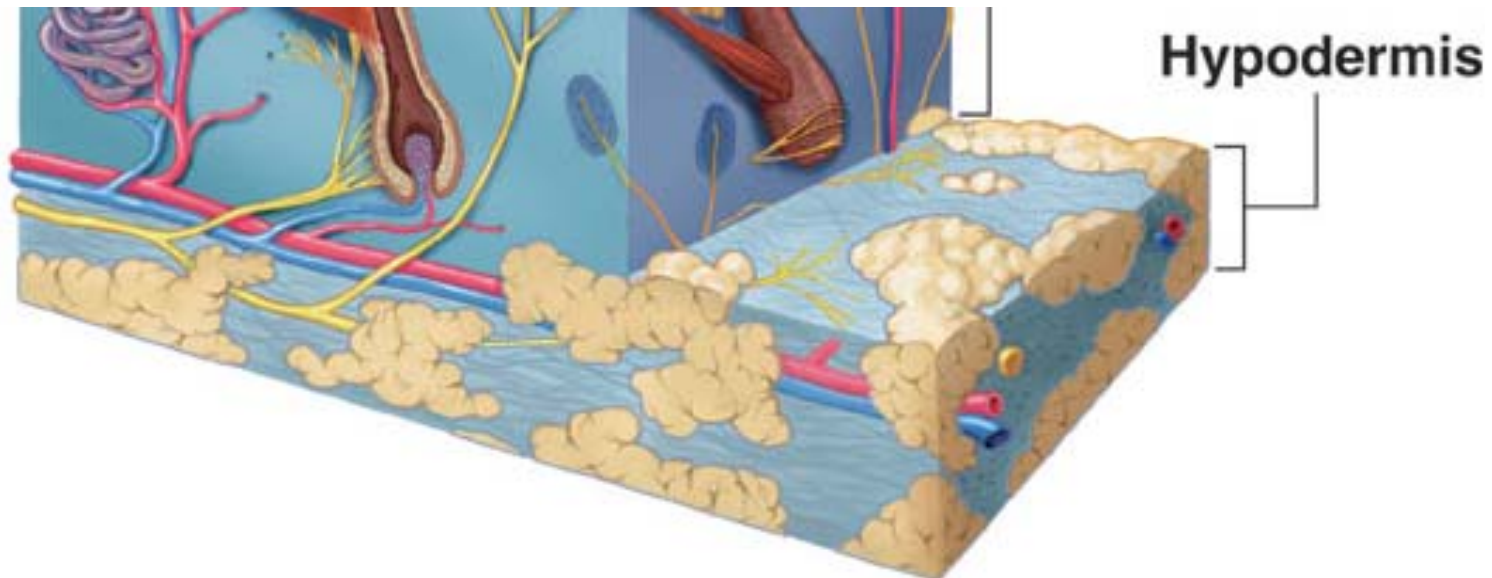
Dermis

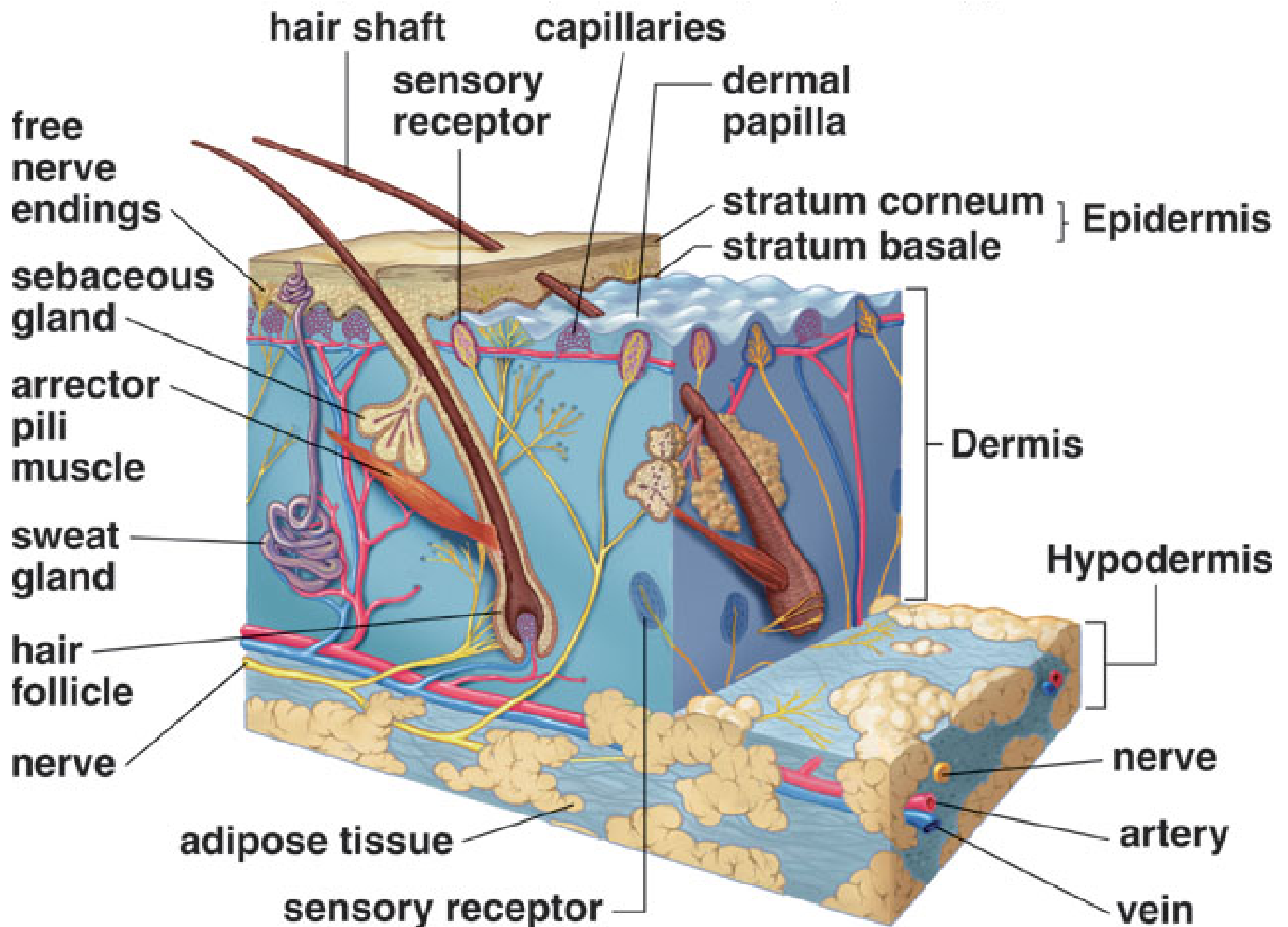
- Collagenous and elastic fibers
- **Vascular**
- Accessory organs



Hypodermis

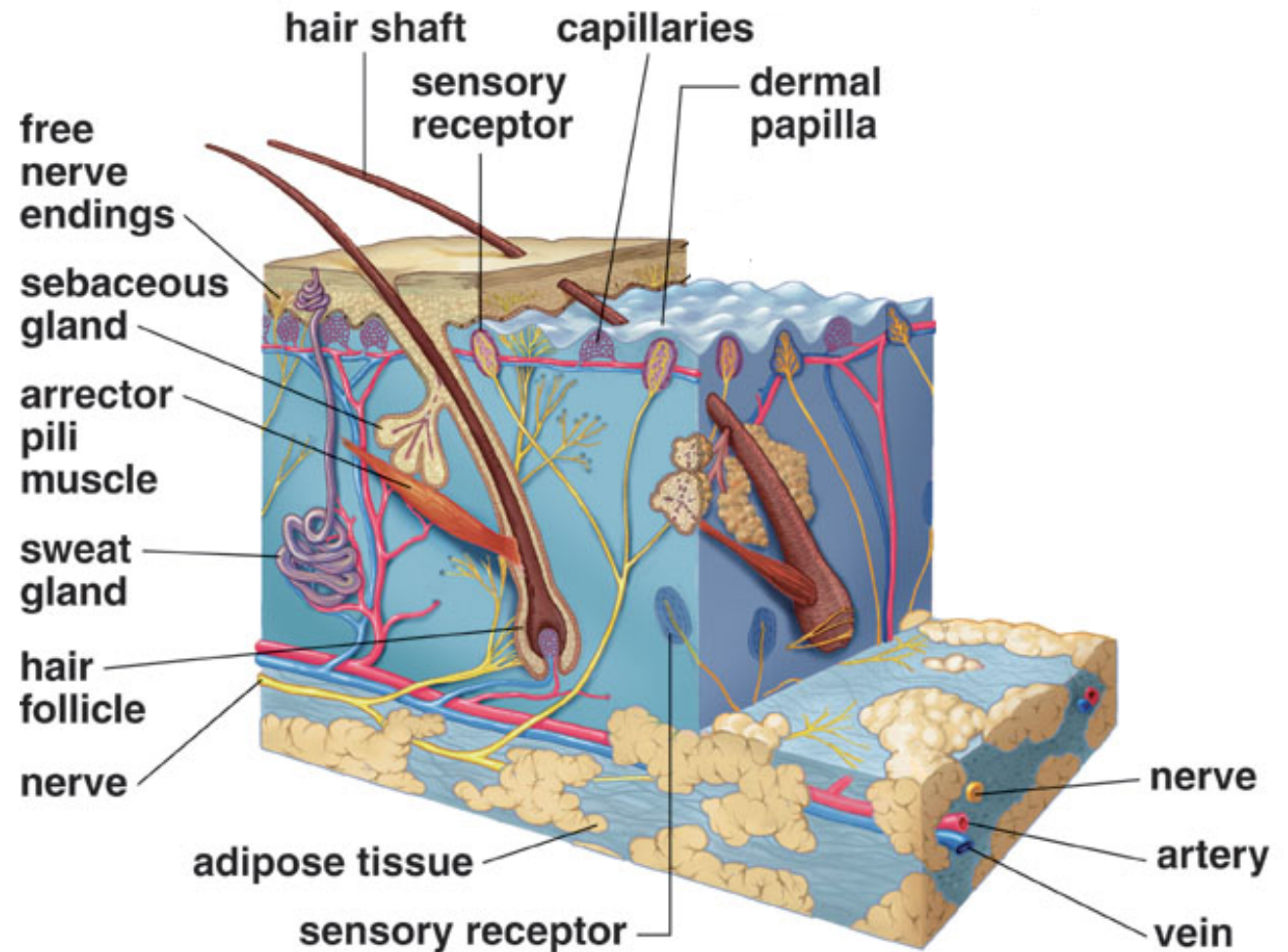
- AKA- **subcutaneous** layer
- Not part of the skin
- Lies below dermis
- Loose Areolar and Adipose (fat) tissue





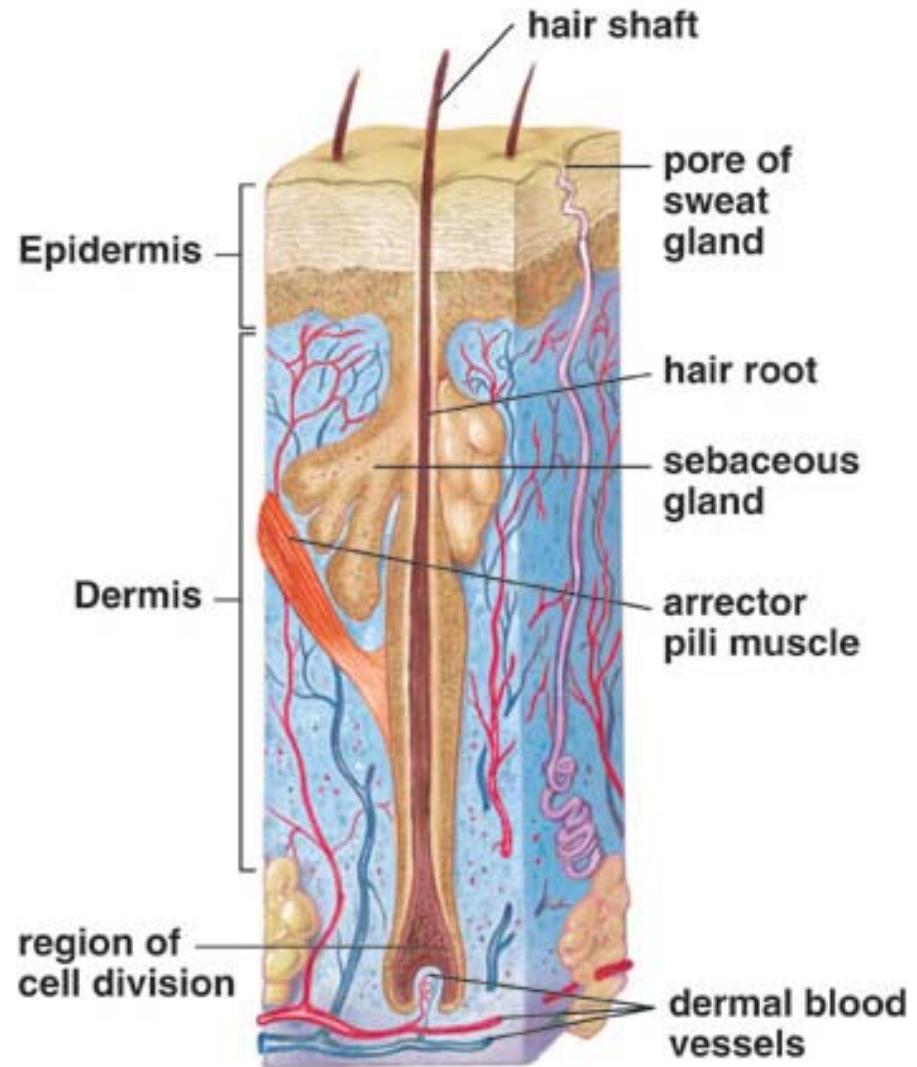
Section 5.2- Accessory Structures of the Skin

- Hairs and Nails
- Glands
- Arrector pili muscle
- Blood vessels



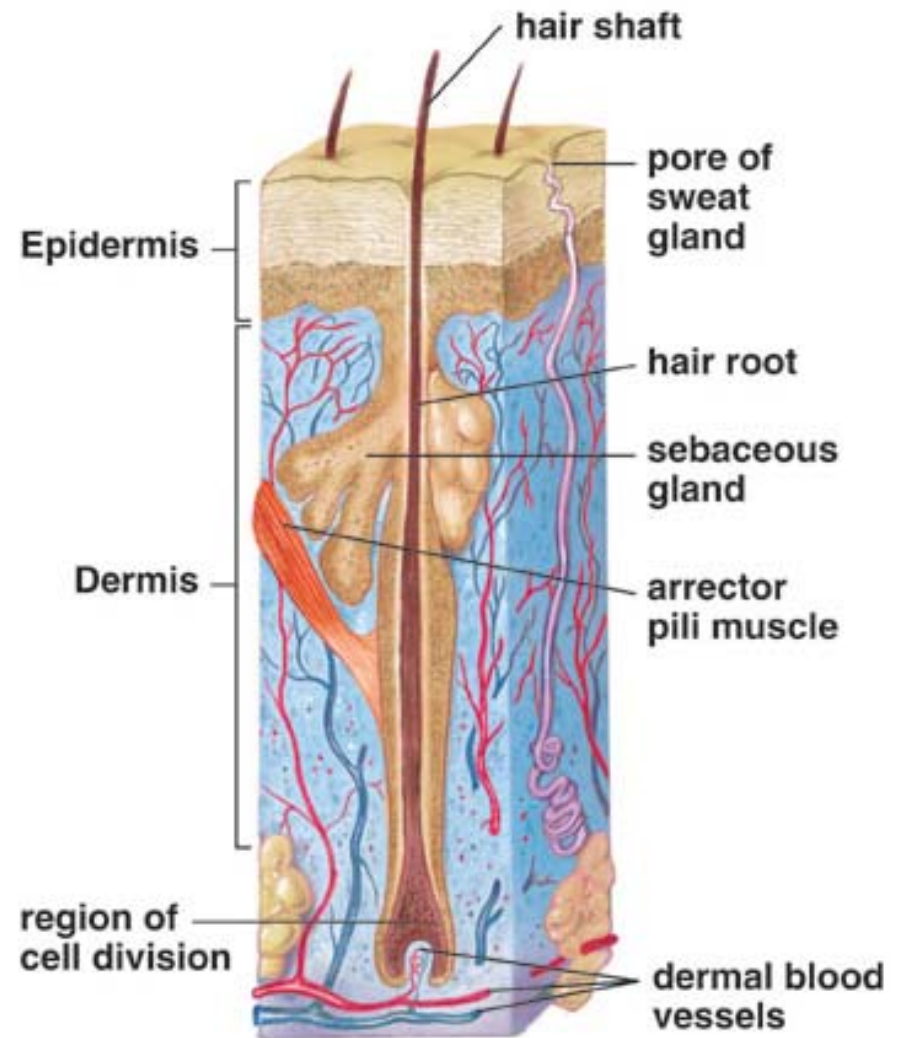
Hair

- Found on all body parts except palms, soles, lips, nipples, and portions of external reproductive organs



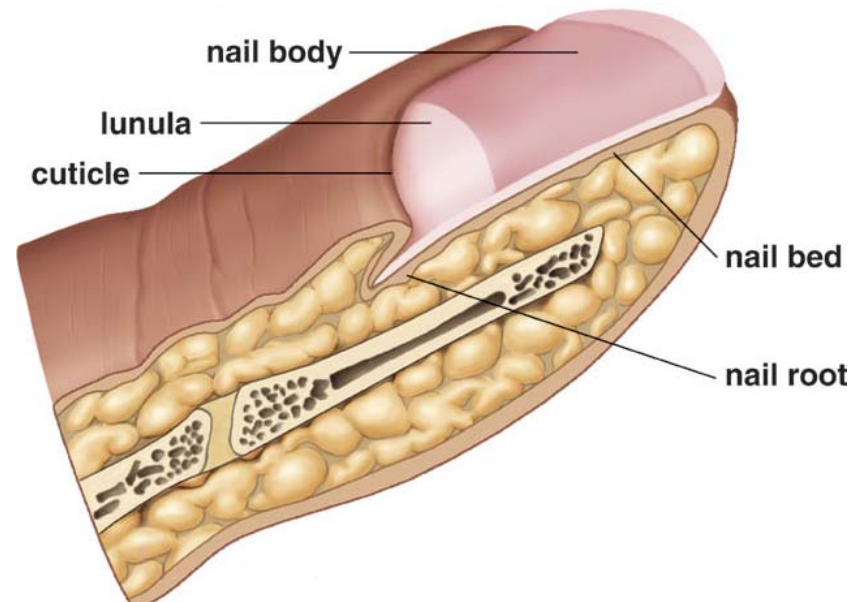
Hair

- Grows from hair follicle located in dermis
 - Cells undergoing mitosis and pushed to surface and die
- Parts of hair
 - Shaft
 - Root
 - follicle
- Sebaceous glands empty oils into follicle
- Arrector pili muscles-
“goose bumps”



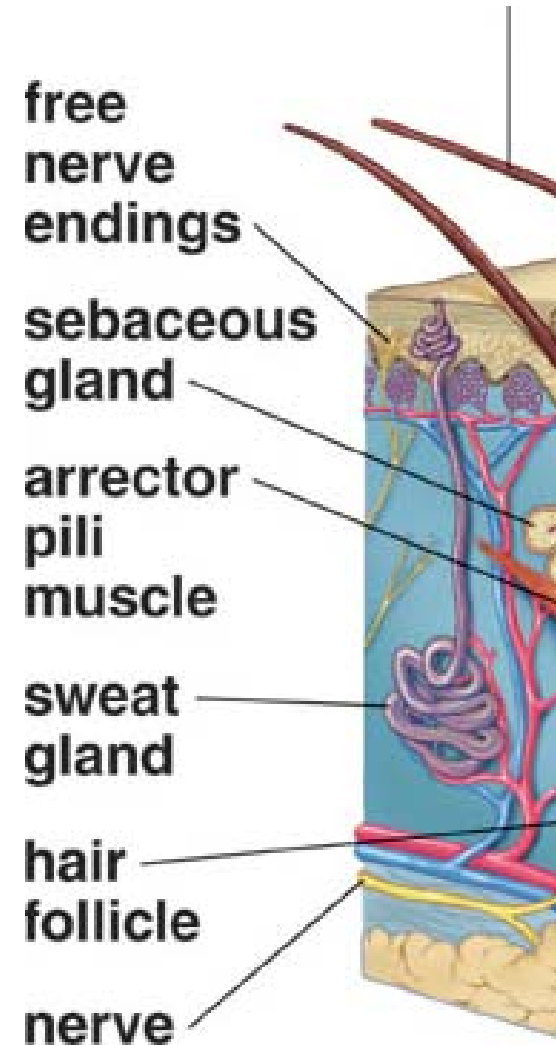
Nails

- Grow from **nail root**
- Nails cover **nail bed** (very vascular)
- **Nail body**- visible
- **Cuticle**- fold of skin that hides nail root
- **Lunula**- moon shape at base of nail



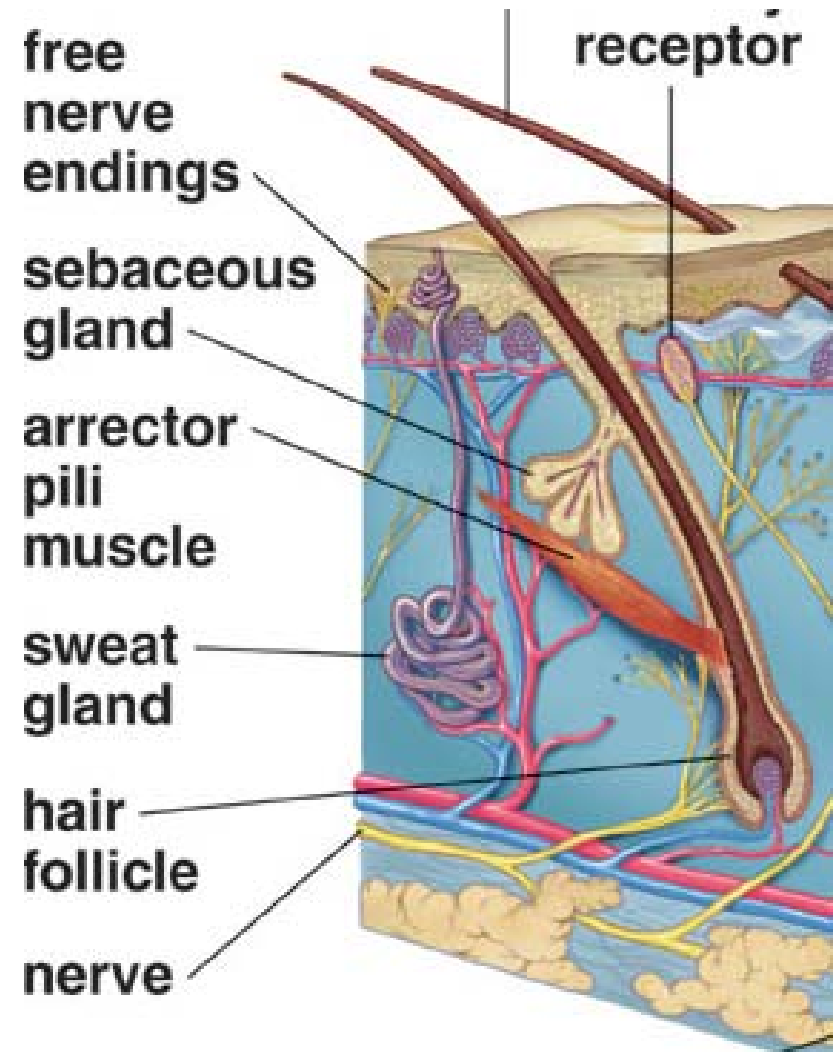
Glands

- Sweat Glands
 - Located in dermis
 - Tubular and coiled at the base
 - Active during stress
 - 2 Types
 - **Apocrine**- anal, groin, and armpits
 - Ducts opens into hair follicles
 - **Eccrine**- everywhere else
 - Ducts opens into skin
- Sweat- water, salts, urea



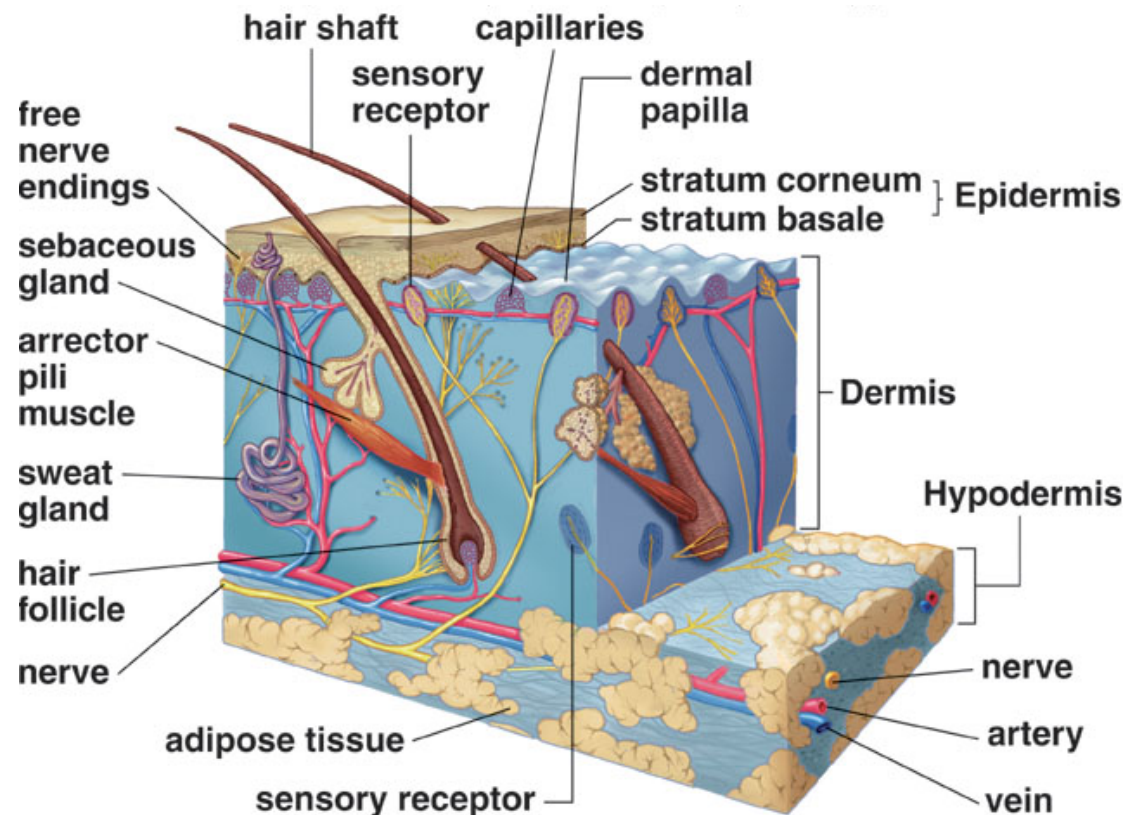
Glands

- Sebaceous Glands
 - Associated with hair follicle
 - Secrete **sebum**-lubricates skin and hair, waterproof
 - Acne
 - Failure to discharge sebum, collects in ducts



Blood Vessels

- Arteries, veins, and capillaries
- Located in the dermis
- Blood supply to the tissues and accessory structures



Sensory Nerves

- Located in the dermis
- Sense pressure, pain, temperature

